

# Measured resection versus gap balancing technique for femoral rotational alignment: a prospective study

Anastasios P Nikolaidis,<sup>1</sup> Eustathios I Kenanidis,<sup>1</sup> Kyriakos A Papavasiliou,<sup>1</sup> Fares E Sayegh,<sup>1</sup> Ioannis Tsitouridis,<sup>2</sup> George A Kapetanios<sup>1</sup>

<sup>1</sup> Third Orthopaedic Department, Aristotle University of Thessaloniki-Medical School, "Papageorgiou" General Hospital, Thessaloniki, Greece

<sup>2</sup> Department of Radiology, "Papageorgiou" General Hospital, Thessaloniki, Greece

---

## ABSTRACT

**Purpose.** To compare the measured resection technique and the gap balancing technique for correction of the femoral rotational alignment.

**Methods.** 57 women and 6 men (mean age, 70 years) with end-stage osteoarthritis and <15° malalignment and <10° flexion contracture of the knee underwent primary total knee arthroplasty through the medial approach using the measured resection technique (n=34) or the gap balancing technique (n=29). Femoral rotational alignment was evaluated before and 7 days after surgery using computed tomography by referencing the 2 posterior condyles to the transepicondylar axis.

**Results.** The 2 groups did not differ significantly in terms of correction of the femoral rotational alignment (3.4°±1.4° vs. 3.5°±3.1°, p=0.817).

**Conclusion.** The measured resection and the gap balancing techniques achieved comparable correction of femoral rotational alignment.

---

**Key words:** arthroplasty, replacement, knee; knee prosthesis

---

## INTRODUCTION

In total knee arthroplasty (TKA), malrotation of the femoral component is associated with patellofemoral maltracking, flexion instability, stiffness, abnormal gait patterns, knee pain, and wear or loosening of the prosthesis.<sup>1-7</sup> Rotational alignment of the femoral component can be determined by the measured resection technique and the gap balancing technique. The former is based on several fixed bony landmarks (such as the transepicondylar axis, the anteroposterior line or Whiteside's line, and the posterior condylar line adding 3° of fixed external rotation), regardless of the tension of the ligaments.<sup>4-6,8</sup> In the latter, the femoral component is positioned parallel to the resected proximal tibia following proper balancing of the collateral ligaments (in both extension and flexion).<sup>1,8,9</sup>

The optimal technique to determine the

rotational alignment of the femoral component remains controversial.<sup>4,6-8,10,11</sup> Reproducibility of both techniques is low.<sup>1,12-15</sup> In the measured resection technique, the landmarks may be difficult to identify.<sup>16,17</sup> Moreover, variability among patients is high in terms of rotation of the distal femur and hypoplasia or wear of the posterior part of the condyles.<sup>4</sup> Whereas the gap balancing technique may be affected by an inappropriate tibial cut and false tensioning of the collateral ligaments.<sup>4</sup> This study compared the 2 techniques in terms of correction of the femoral rotational alignment.

## MATERIALS AND METHODS

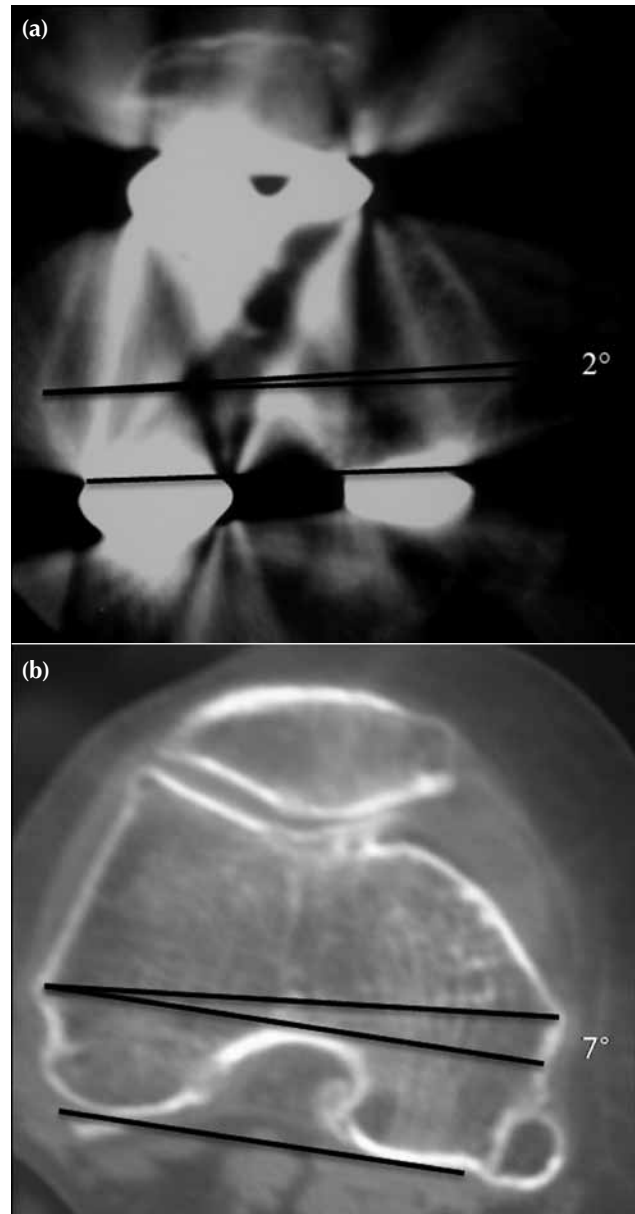
This study was approved by the scientific research board of our institution and conducted in accordance with the Declaration of Helsinki. Informed consent was obtained from each patient. The sample size was estimated from previous studies according to the mean difference in external rotation of the femoral component between the 2 techniques.<sup>8</sup> Based on such a difference of 0° to 3°,<sup>8,10</sup> at least 29 patients were needed in each group to detect a mean difference of 3° (standard deviation [SD], 4°), with a power of 0.8 and an  $\alpha$  value of 0.05.

Between February 2007 and October 2009, 57 women and 6 men (mean±SD age, 70±6 years) with end-stage osteoarthritis and <15° malalignment and <10° flexion contracture of the knee underwent primary TKA through the medial approach using the measured resection technique (n=34) or the gap balancing technique (n=29). Patients were non-randomly allocated; a single experienced knee surgeon used a single implant design in each group. Patients with any previous knee operation were excluded, as were those in whom appropriate landmarks could not be identified in preoperative computed tomography.

In the measured resection group, the Medial Rotation Knee (Finsbury Orthopaedics, Leatherhead, UK) prosthesis was used. The posterior condylar line was used to determine the proper rotation of the femoral component. The tibial cut was made using an external tibial alignment system. The intramedullary femoral rod was then inserted 5 to 10 mm proximal to the intercondylar notch and 5 to 10 mm medial to the midline. The femoral resection guide was attached to the intramedullary femoral rod, assembled with a femoral alignment jig allowing 3° of fixed external rotation.

In the gap balancing group, the GMK Primary (Medacta International, Switzerland) prosthesis was

used. The proximal tibial cut was perpendicular to the mechanical axis of the tibia, using an external tibial alignment system attached to the proximal tibia and to the ankle. Alignment and soft-tissue balancing were assessed in extension. An intramedullary femoral rod attached with a cutting block guided a 5° valgus distal cut. A rotationally unconstrained



**Figure** (a) Femoral rotational alignment is calculated by referencing a line drawn tangent to the most posterior part of the femoral condyles to the transepicondylar axis, which is a line drawn from the lateral epicondyle to the most prominent point of the medial epicondyle. (b) The rotational deviation of the femoral component is determined by an angle between the line connecting the posterior condylar line of the femoral implant and the transepicondylar axis.

femoral resection guide was then inserted on top of the resected distal osteotomy. A rectangular spacer block was applied to the femoral resection guide and placed parallel to the resected proximal tibia to determine the femoral rotation cut.

Femoral rotational alignment was evaluated before and 7 days after surgery using computed tomography. Patients were placed in a supine position, with the affected leg in full extension using an anti-rotation boot. Two-mm thick images perpendicular to the long axis of the leg were taken from the distal femoral metaphysis to the tibial tubercle. Images were evaluated by a consultant orthopaedic surgeon and a musculoskeletal radiologist who were blinded to the techniques used. Femoral rotational alignment was calculated by referencing the 2 posterior condyles (a line drawn tangent to the most posterior part of the condyles) to the transepicondylar axis, which is a line drawn from the lateral epicondyle to the most prominent point of the medial epicondyle (Fig.). The rotational deviation of the femoral component was determined by an angle between the line connecting the posterior condylar line of the femoral implant and the transepicondylar axis (Fig.).

The normality of groups' data distribution was tested using the Kolmogorov-Smirnov test or the Shapiro-Wilk test. The hypothesis of equality of means was discarded when the probability of a type-I error was  $\leq 5\%$ . All tests were 2-tailed. Kappa coefficient was used to determine the interobserver reliability between the orthopaedic surgeon and the radiologist. Independent sample *t*-test was used to compare the femoral rotation alignment between the 2 groups. The Mann-Whitney *U* test was used to compare the correction of the femoral rotational alignment between the 2 groups. The Pearson Chi squared test was used to compare the proportion of patients with rotational deformity  $<3^\circ$  or  $>3^\circ$ , and with rotational correction of  $>5^\circ$  between the 2 groups.

## RESULTS

The interobserver variability for rotational alignment of the femoral component was 0.856. The respective measured resection and gap balancing groups did not differ significantly in terms of preoperative femoral rotational alignment ( $6.4^\circ \pm 1.4^\circ$  vs.  $5.9^\circ \pm 1.6^\circ$ ,

**Table**  
**Comparison of patients in the measured resection and gap balancing technique groups**

Parameter	Measured resection technique	Gap balancing technique	p Value
Mean $\pm$ SD age (years)	71 $\pm$ 6	70 $\pm$ 6	0.455 (Mann-Whitney <i>U</i> test)
No. (%) of patients			0.286 (Chi squared test)
Males	2 (6)	4 (14)	
Females	32 (94)	25 (86)	
Femorotibial alignment (no. [%] of patients)			0.778 (Chi squared test)
Varus	31 (91)	27 (93)	
Valgus	3 (9)	2 (7)	
Mean $\pm$ SD femoral rotational alignment			
All patients			
Preop	6.4 $\pm$ 1.4 $^\circ$	5.9 $\pm$ 1.6 $^\circ$	0.246 (independent sample <i>t</i> -test)
Postop day 7	3.0 $\pm$ 1.5 $^\circ$	2.5 $\pm$ 3.1 $^\circ$	0.413 (independent sample <i>t</i> -test)
Correction	3.4 $\pm$ 1.4 $^\circ$	3.5 $\pm$ 3.1 $^\circ$	0.817 (Mann-Whitney <i>U</i> test)
Females			
Preop	6.5 $\pm$ 1.4 $^\circ$	6.1 $\pm$ 1.5 $^\circ$	0.328 (independent sample <i>t</i> -test)
Postop day 7	3.0 $\pm$ 1.4 $^\circ$	2.2 $\pm$ 3.1 $^\circ$	0.162 (independent sample <i>t</i> -test)
Correction	3.5 $\pm$ 1.4 $^\circ$	4.0 $\pm$ 2.0 $^\circ$	0.584 (Mann-Whitney <i>U</i> test)
Femoral component alignment in reference to the transepicondylar axis (no. [%] of patients)			
All patients			0.283 (Chi squared test)
$<3^\circ$	21 (62)	14 (48)	
$>3^\circ$	13 (38)	15 (51)	
Females			0.426 (Chi squared test)
$<3^\circ$	20 (63)	13 (52)	
$>3^\circ$	12 (38)	12 (48)	
Femoral rotational alignment correction $>5^\circ$ (no. [%] of patients)			
All patients	3 (9)	7 (24)	0.095 (Chi squared test)
Females	3 (9)	7 (28)	0.067 (Chi squared test)

$p=0.246$ ), postoperative rotational alignment of the femoral component ( $3.0^{\circ}\pm 1.5^{\circ}$  vs.  $2.5^{\circ}\pm 3.1^{\circ}$ ,  $p=0.413$ ), correction of the femoral rotational alignment ( $3.4^{\circ}\pm 1.4^{\circ}$  vs.  $3.5^{\circ}\pm 3.1^{\circ}$ ,  $p=0.817$ ), proportion of patients with the femoral component not aligned within  $3^{\circ}$  with reference to the transepicondylar axis (38% vs. 51%,  $p=0.283$ ), and proportion of patients with correction of the femoral rotational alignment of  $>5^{\circ}$  (9% vs. 24%,  $p=0.095$ ). The corresponding values between females of the 2 groups also did not differ significantly (Table).

## DISCUSSION

Correct rotational alignment of the femoral component enables proper kinematics in TKA.<sup>18</sup> Placing the femoral component parallel to the transepicondylar axis leads to a biomechanically sound knee motion in flexion and extension.<sup>5</sup> The effects of excessive external or internal rotation of the femoral component are detrimental.<sup>19–21</sup> Whether the measured resection or gap balancing technique is better in determining the rotational alignment of the femoral component remains controversial.<sup>4,8,10,11</sup>

The gap balancing technique enables better coronal stability, based on the incidence and magnitude of the femoral condylar lift-off,<sup>22</sup> but surgical technique alone only contributes to part of the kinematics.

Preoperative femoral rotational alignment may influence postoperative rotation alignment of the femoral component, which is mainly determined by the degree of the ligamentous release and an accurate tibial cut; valgus knees show more external rotation of the femoral component than varus knees.<sup>4,6</sup>

In the measured resection technique, the landmarks may be difficult to identify.<sup>16,17</sup> Only 75% of knees are aligned within  $3^{\circ}$  of the true epicondylar axis when the epicondyles are used to determine the rotational alignment.<sup>16</sup> When the posterior condylar axis is used to determine the rotational alignment, the

variability of the femoral rotational alignment among patients renders the  $3^{\circ}$  of fixed external rotation of the femoral component insufficient for some patients.<sup>7</sup> Moreover, the posterior condylar axis may be misleading because of degeneration of the posterior condyles, especially in valgus knees.<sup>4</sup>

Women tend to have more valgus alignment and smaller distal femur of a different shape compared with men.<sup>23,24</sup>

One limitation of this study was that patients were not randomised. Nonetheless, patients were consecutive and matched between groups, and only a single experienced knee surgeon used a single implant design in each group. Another limitation was that radiographic findings did not correlate with clinical symptoms or intra-operative measurements. Nonetheless, femoral component malrotation is associated with numerous clinical consequences.<sup>4,5,25</sup> The use of transepicondylar axis as a reference for rotational alignment of the femoral component may have introduced biases. Despite a growing consensus that optimal rotational alignment of the femoral component should be parallel to the transepicondylar axis,<sup>7</sup> the transepicondylar axis may alter in varus and valgus knees or other pathological variations<sup>5</sup> and has low reproducibility during TKA.<sup>12–15</sup> In addition, the osteoarthritic process may influence the transepicondylar axis measurement due to cartilage erosion, particularly in the posterior condyles.

## CONCLUSION

The measured resection and the gap balancing techniques achieved comparable correction of femoral rotational alignment.

## DISCLOSURE

No conflicts of interest were declared by the authors.

## REFERENCES

1. Aglietti P, Sensi L, Cuomo P, Ciardullo A. Rotational position of femoral and tibial components in TKA using the femoral transepicondylar axis. *Clin Orthop Relat Res* 2008;466:2751–5.
2. Benjamin J. Determining femoral component position using CAS and measured resection. *Clin Orthop Relat Res* 2008;466:2745–50.
3. Boldt JG, Stiehl JB, Hodler J, Zanetti M, Munzinger U. Femoral component rotation and arthrofibrosis following mobile-bearing total knee arthroplasty. *Int Orthop* 2006;30:420–5.
4. Dennis DA, Komistek RD, Kim RH, Sharma A. Gap balancing versus measured resection technique for total knee arthroplasty. *Clin Orthop Relat Res* 2010;468:102–7.

5. Hamelynck KJ, Stiehl JB. LCS mobile bearing knee arthroplasty 25 years of world wide experience. In: James V. Bono, Richard D. Scott, editors. Revision total knee arthroplasty. New York: Springer; 2002:175–81.
6. Heesterbeek PJ, Jacobs WC, Wymenga AB. Effects of the balanced gap technique on femoral component rotation in TKA. *Clin Orthop Relat Res* 2009;467:1015–22.
7. Victor J. Rotational alignment of the distal femur: a literature review. *Orthop Traumatol Surg Rev* 2009;95:365–72.
8. Fehring TK. Rotational malalignment of the femoral component in total knee arthroplasty. *Clin Orthop Relat Res* 2000;380:72–9.
9. Katz MA, Beck TD, Silber JS, Seldes RM, Lotke PA. Determining femoral rotational alignment in total knee arthroplasty: reliability of techniques. *J Arthroplasty* 2001;16:301–5.
10. Laskin RS. Flexion space configuration in total knee arthroplasty. *J Arthroplasty* 1995;10:657–60.
11. Hanada H, Whiteside LA, Steiger J, Dyer P, Naito M. Bone landmarks are more reliable than tensioned gaps in TKA component alignment. *Clin Orthop Relat Res* 2007;462:137–42.
12. Galaud B, Beaufils P, Michaut M, Abadie P, Fallet L, Boisrenoult P. Distal femoral torsion: comparison of CT scan and intra-operative navigation instruments during total knee arthroplasty. A report of 70 cases [in French]. *Rev Chir Orthop Reparatrice Appar Mot* 2008;94:573–9.
13. Jenny JY, Boeri C. Low reproducibility of the intra-operative measurement of the transepicondylar axis during total knee replacement. *Acta Orthop Scand* 2004;75:74–7.
14. Siston RA, Patel JJ, Goodman SB, Delp SL, Giori NJ. The variability of femoral rotational alignment in total knee arthroplasty. *J Bone Joint Surg Am* 2005;87:2276–80.
15. Talbot S, Bartlett J. The anterior surface of the femur as a new landmark for femoral component rotation in total knee arthroplasty. *Knee Surg Sports Traumatol Arthrosc* 2008;16:258–62.
16. Kinzel V, Ledger M, Shakespeare D. Can the epicondylar axis be defined accurately in total knee arthroplasty? *Knee* 2005;12:293–6.
17. Yau WP, Chiu KY, Tang WM. How precise is the determination of rotational alignment of the femoral prosthesis in total knee arthroplasty: an in vivo study. *J Arthroplasty* 2007;22:1042–8.
18. Bull AM, Kessler O, Alam M, Amis AA. Changes in knee kinematics reflect the articular geometry after arthroplasty. *Clin Orthop Relat Res* 2008;466:2491–9.
19. Berger RA, Crossett LS, Jacobs JJ, Rubash HE. Malrotation causing patellofemoral complications after total knee arthroplasty. *Clin Orthop Relat Res* 1998;356:144–53.
20. Poilvache PL, Insall JN, Scuderi GR, Font-Rodriguez DE. Rotational landmarks and sizing of the distal femur in total knee arthroplasty. *Clin Orthop Relat Res* 1996;331:35–46.
21. Scuderi GR, Komistek RD, Dennis DA, Insall JN. The impact of femoral component rotational alignment on condylar lift-off. *Clin Orthop Relat Res* 2003;410:148–54.
22. Dennis DA. Measured resection: an outdated technique in total knee arthroplasty. *Orthopedics* 2008;31:940–4.
23. Chin KR, Dalury DF, Zurakowski D, Scott RD. Intraoperative measurements of male and female distal femurs during primary total knee arthroplasty. *J Knee Surg* 2002;15:213–7.
24. Hitt K, Shurman JR 2nd, Greene K, McCarthy J, Moskal J, Hoeman T, et al. Anthropometric measurements of the human knee: correlation to the sizing of current knee arthroplasty systems. *J Bone Joint Surg Am* 2003;85(Suppl 4):115–22.
25. Chung BJ, Kang YG, Chang CB, Kim SJ, Kim TK. Differences between sagittal femoral mechanical and distal reference axes should be considered in navigated TKA. *Clin Orthop Relat Res* 2009;467:2403–13.