

Osteoarthritis and Cartilage



Calcitonin delays the progress of early-stage mechanically induced osteoarthritis. *In vivo*, prospective study[☆]



M.J. Kyrkos^{†*}, K.A. Papavasiliou[‡], E. Kenanidis[‡], E. Tsiridis[‡], F.E. Sayegh[‡], G.A. Kapetanios[‡]

[†]3rd Orthopaedic Department, Aristotle University Medical School, Thessaloniki, Greece

[‡]Imperial College London Medical School, Department of Surgery and Cancer, Division of Surgery, B-block Hammersmith, Du-Cane Road, London W12 0HS, UK

ARTICLE INFO

Article history:

Received 19 October 2012

Accepted 13 March 2013

Keywords:

Calcitonin

Osteoarthritis

Experimental osteoarthritis

SUMMARY

Background/rationale: Introducing new or testing existing drugs in an attempt to modify the progress of osteoarthritis (OA) is of paramount importance.

Questions/purposes: This study aims to determine the effect exerted by Calcitonin on the progress of early-stage osteoarthritic lesions.

Methods: We used 18, skeletally mature, white, female, New Zealand rabbits. OA was operatively induced in the right knee of each animal by the complete dissection of the anterior cruciate ligament, complete medial meniscectomy and partial dissection of the medial collateral ligament. Postoperatively, animals were divided into two groups. Starting on the ninth postoperative day and daily thereafter, group A animals ($n = 9$) received 10 IU oculus dexter (o.d.) of synthetic Calcitonin IntraMuscularly (I.M.); group B animals ($n = 9$) received equal volume of saline o.d. Three animals from each group were sacrificed at 1, 2 and 3 months following treatment's initiation. The extent and the grade of OA were assessed macroscopically, histologically and by radiographs, Computed Tomography (CT) and Magnetic Resonance Imaging (MRI)-scans. The Osteoarthritis Research Society International (OARSI) score, incorporating histological and macroscopic information, was calculated for each knee.

Results: Osteoarthritic changes in group A animals were less severe and progressed less rapidly when compared with those of group B animals (sham). This difference was statistically significant in the first and second month ($P = 0.05$), but not in the third month ($P = 0.513$).

Conclusions: I.M. administration of Calcitonin seems to delay the progress of early-stage osteoarthritic lesions induced by mechanical instability in a rabbit experimental model.

© 2013 Osteoarthritis Research Society International. Published by Elsevier Ltd. All rights reserved.

Introduction

Osteoarthritis (OA) affects nearly 27 million Americans¹. The total annual cost of OA per person living with OA is \$5,700². If these two numbers are combined the magnitude of the importance of treatment of OA is beginning to emerge. The pharmacological agents that have been commonly used in order to treat patients suffering from OA are known either as Symptom Modifying OsteoArthritis Drugs (SMOADs), such as pain relievers and Non-Steroidal Anti-Inflammatory Drugs (NSAIDs), or Disease Modifying OsteoArthritis Drugs (DMOADs) that include Chondroitin Sulfate, Glucosamine Sulfate and Diacerein, as well as the newer DMOADs that are under evaluation. The latest drugs, belonging to

the DMOADs group, that are currently developed can be broadly divided into four categories, regarding their pathway through which they affect progression of OA. These are: genetics, cartilage metabolism, synovial inflammation and remodeling of subchondral bone. This last group regarding the remodeling of the subchondral bone includes Bisphosphonates, Strontium Ranelate and Calcitonin, among others³.

The hyaline cartilage of the joints is deprived of blood vessels and its integrity greatly depends on the status of the subchondral bone⁴. If the subchondral bone could be 'assisted' by an anti-osteoclastic agent, such as Calcitonin, then it is possible that the overlying articular cartilage would be positively affected as well. Furthermore, there is evidence (even though sometimes conflicting) that Calcitonin might interfere in a therapeutic manner with the metabolism of cartilage and chondrocyte, especially in patients suffering from OA^{5–8}. Calcitonin has been used since 1984 (Food and Drug Administration (FDA) approval) in osteoporosis treatment and Paget's disease due to its anti-osteoclastic action and its pain relieving effect⁹.

[☆] **Work performed at:** Aristotle University Medical School, Thessaloniki, Greece.

* Address correspondence and reprint requests to: M.J. Kyrkos, 138 Al. Papanastasiou Street, 542 49 Thessaloniki, Greece. Tel/Fax: 30 2310310930.

E-mail address: mjkyrkos@hotmail.com (M.J. Kyrkos).

Aim of this experimental study was to test the hypothesis that the administration of Calcitonin delays the progress of mechanically induced osteoarthritic lesions in a drastic model of experimentally induced OA in rabbits and to evaluate the results by radiography, Computed Tomography (CT)-scan, Magnetic Resonance Imaging (MRI)-scan, macroscopically and histologically.

Materials and method

This study was performed on eighteen skeletally mature, female, white, New Zealand rabbits. All animals were 1 year-old and their mean weight was five kilograms (± 500 g). Skeletal maturity was confirmed radiographically. OA was operatively induced on all animals^{10–12}. All operations took place under general anesthesia (ketamine 25 mg/kg and midazolam 5 mg/kg). Following a medial parapatellar exposure to the right knee of each animal, a complete dissection of the cranial cruciate ligament was performed, combined with a complete medial meniscectomy and a partial dissection of the medial collateral ligament. This surgical intervention aimed to create instability, which in turn would induce OA and also simulate a common injury pattern of the human knee, the “O’Donoghue’s” or “terrible” triad of the knee. Absorbable sutures were used for the closure of the wound. Postoperatively, all animals received intramuscularly enrofloxacin (3 mg/kg/24 h) for 5 days. Rabbits were singly housed in cages sized 0.5 m \times 1.1 m \times 0.5 m and had free access to rabbit pellets and water.

On the seventh postoperative day, the bandages were removed and the animals were randomly divided into two groups of nine rabbits each. Starting on the ninth postoperative day, the animals of the first group (Group A) received daily 10 I.U. of synthetic salmon Calcitonin intramuscularly, while the ones of the second group (Group B–Placebo) received equal volume of saline (1 ml) daily. Three animals from each group were sacrificed at 1, 2 and 3 months following the initiation of treatment. The animals were sacrificed by receiving intramuscularly ketamine and midazolam and then intravenously sodium thiopental. Following their sacrifice, the imaging evaluation, consisting of standard antero-posterior and lateral radiographs, CT-scan and MRI-scan of the knees, was taking place. The CT-scan tomographies had a thickness of 1.5 mm, while the MRI-scan (1.5 T) ones had 2 mm thickness. The knee joint was then exposed and by carefully removing all the soft tissues, we performed the macroscopic evaluation of the articular surface of both the femoral and the tibial condyles. Both articular surfaces were photographed, directly perpendicularly, from a standard distance of 10 cm with a digital camera (Hewlett Packard R 607) and the photographs were edited with a photo editing software (Adobe Photoshop CS2) in order to outline both the osteoarthritic lesions and the total articular surface. Following that procedure, the two outlined areas were painted and projected onto the same photograph and with the aid of the Auto Computer Aided Design 2006 (Autodesk) software the exact percentage of the area of the articular surface that showed osteoarthritic lesions was calculated. This procedure allowed the easy and accurate calculation of the exact percentage of the area of the articular surface of the femoral or tibial condyles that was degenerated. Finally all specimens were histologically evaluated as well after being standardized in formaldehyde solution 10% for 48 h and demineralized in solution of 5% nitric acid and 5% formaldehyde. Slides of 2 mm thickness were then obtained that were processed with solutions of 10% formaldehyde, alcohol (70°, 80°, 96°, 96° and 100°), acetone, xylene and paraffin. Following this preparation, slides of 4 μ thickness were obtained and were dyed with hematoxylin-eosin stain, while the magnification used in the optical microscopy ranged from $\times 20$ to $\times 400$.

The Chan *et al.*¹³ grading system was used to evaluate the imaging techniques. This system is based on the observation of four

parameters: (1) loss or degeneration of articular cartilage, (2) subchondral bone sclerosis, (3) osteophyte formation and (4) appearance of subchondral cysts. Each parameter gets a grade between 0 and 3 (0 is for normal appearance and 3 is for a completely degenerated joint). The final grade is calculated as the sum of the grades for every parameter in the radiographs, CT-scan and MRI-scan. The more osteoarthritic changes appear in a joint, the higher is the score. There were separate grades for the femoral and the tibial articular surfaces.

The OARSI (Osteoarthritis Research Society International) grading system¹⁴ was used for the histological assessment. This score ranges from 0 to 6 (0 is for normal appearance and 6 is for advanced osteoarthritic changes). We preferred this grading system because it grades both the depth of the lesions (grade) as well as their area (stage). As a result the final outcome of the OARSI grading system is the result of (grade) \times (stage). As ‘stage’ of the osteoarthritic lesions we used the exact percentage of the articular surface that showed osteoarthritic lesions. This percentage was calculated by the photography and computer-aided method described.

The normality of the data distribution among different groups was tested according to the Shapiro–Wilk test. All statistical tests were two-tailed. The alpha level for all analyses was set at 0.05. All analyses were performed with the SPSS statistical software (Version 12, Chicago-IL). The Mann–Whitney test was used to determine the asymptomatic significance of the differences found in the median imaging score between the ‘Calcitonin’ and the ‘placebo’ groups.

Results

Osteoarthritic lesions (of various degrees) were found in the knee joints of all the animals in the imaging, macroscopic and histological evaluation (Table I). Almost all the results of the group A animals (Calcitonin) were better than the results of the placebo group (group B) in every method of evaluation.

The mean score regarding the imaging results (sum of all the scores in radiographic, CT and MRI evaluation) for group A (Calcitonin) were 5.5 for the animals sacrificed in the first month, 14.33 for the animals of the second month and 22.83 for the animals sacrificed in the third month. The results for the group B animals (Placebo) were 11.33 for the first month, 19.17 for the second month and 24.17 for the third month respectively, with higher score meaning worse osteoarthritic findings (joint space narrowing, osteophytes, bone cysts, subchondral sclerosis) in the imaging evaluation (Figs 1–5).

The mean percentage of the area covered by osteoarthritic lesions in group A was 14.3% for the first month, 18.7% for the second month and 27.7% for the third month. Group B results were: 18.1% for the first month, 23.3% for the second and 29.1% for the third month respectively.

Statistical analysis (Table II) showed statistically significant difference (favoring group A) between the imaging results of the femoral condyles of the animals of group A and B that were sacrificed in the first and second month ($P = 0.046$) and the imaging results of the tibial condyles of the animals sacrificed in the second month postoperatively ($P = 0.046$). Statistically significant difference also existed between the two groups in the imaging results of the tibia in the animals that were sacrificed on the second postoperative month. There was a tendency toward significance between the imaging results of the tibial condyles of the two groups in the animals that were sacrificed in the first postoperative month, while no statistically significant difference was found between the two groups in the animals sacrificed in the third month. Finally there was a statistically significant difference ($P = 0.05$) between the two groups (favoring group A) in the histological

Table 1
Results

Specimen	X-ray	MRI	Sclerosis X-ray	Sclerosis CT	Sclerosis MRI	Osteo X-ray	Osteo CT	Osteo MRI	Cyst X-ray	Cyst CT	Cyst MRI	SUM	Histology	Lesion %	OARSI
Group A mean value	0,3333	0,3333	0,3333	0	0,1667	1	1	1	0,5	0,833	0	5,5	4,1667	14,3	0,5886
Group B mean value	1	1	1	0,6667	1	1,3333	1,1667	1	1,3333	1,167	0,6667	11,33	4	18,090	0,7236
Group AA mean value	0,6667	1	1,3333	1,6667	1,3333	1,3333	1,3333	1,3333	1,3333	1,333	1,6667	14,33	4,3333	18,687	0,8261
Group BB mean value	2	1,667	1,5	1,3333	1	2	2	2	1,8333	2	1,8333	19,17	3,6667	25,3425	0,9292
Group AAA mean value	2	1,667	2,1667	2	2,3333	2,3333	2	2,3333	2	2	2	22,8333	4,3333	27,7450	1,2073
Group BBB mean value	2,3333	2,333	2,3333	2,1667	1,8333	2,1667	2,1667	2,3333	2,1667	2,3333	2	24,1667	4,3333	29,065	1,2397

X-ray: Joint space narrowing (cartilage loss) evaluated from radiographs, MRI: Joint space narrowing (cartilage loss) evaluated from MRI-scan, Sclerosis X-ray: Subchondral sclerosis as seen on radiographs, Sclerosis CT: Subchondral sclerosis as seen on CT-scan, Sclerosis MRI: Subchondral sclerosis as seen on MRI-scan, Osteo X-ray: Osteophytes as evaluated from radiographs, Osteo CT: Osteophytes as evaluated from CT-scan, Osteo MRI: Osteophytes as evaluated from MRI-scan, Cyst X-ray: Subchondral cysts as seen in radiographs, Cyst CT: Subchondral cysts as seen in CT-scan, Cyst MRI: Subchondral cysts as seen in MRI-scan, SUM: Final grade according to Chan *et al.* grading system, Histology: Grade regarding the depth of the osteoarthritic lesion, according to Pritzker *et al.*¹⁰, Lesion %: Percentage of the area of the total articular surface that has been degenerated, OARSI: Final OARSI score according to Pritzker *et al.*¹⁰, A: Animal of the Calcitonin group sacrificed 1 month after initiation of administration of Calcitonin, AA: Animal of the Calcitonin group sacrificed 2 months after initiation of administration of Calcitonin, AAA: Animal of the Calcitonin group sacrificed 3 months after initiation of administration of Calcitonin, B: Animal of the Placebo group sacrificed 1 month after initiation of administration of placebo, BB: Animal of the Placebo group sacrificed 2 months after initiation of administration of placebo, BBB: Animal of the Placebo group sacrificed 3 months after initiation of administration of placebo.

results, regarding the tibial stage (area of lesion in the articular surface) in the animals that were sacrificed on the second post-operative month. Despite the fact that the Calcitonin group had overall better results in all the parameters, no other statistically significant difference was noted.

Discussion

OA is the commonest joint disorder in humans^{15,16}. Conservative treatment, apart from auxiliary modalities such as weight loss, change of lifestyle, exercise, use of walking aids and physiotherapy, is mostly dependant on the use of NSAIDs, which in turn can cause problems from the gastrointestinal and circulatory system^{17,18}. The newer drugs of the DMOADs group, such as Chondroitin Sulfate, Glucosamine Sulfate and Diacerein have controversial results, as some scientists report satisfactory results^{19–21}, while others question their efficacy²². Most of the trials carried-out to test the efficacy of these drugs are based upon radiographic criteria²² for the evaluation of the patients' results, and therefore have been questioned by others as insufficiently prepared and documented²³. Bisphosphonates and especially

Risedronate has been tested as a potent DMOAD agent (targeting the remodeling of the subchondral bone), but despite the fact that in a Phase-II clinical trial it was shown to reduce CTX-II levels²⁴, it failed to show any disease modifying effect in knee OA patients in a Phase-III clinical trial²⁵. Recently, another drug belonging to the same category, Strontium Ranelate, which both reduces bone resorption and increases bone formation, has been used in a clinical trial and has been shown to reduce the progression of radiographic features of spinal OA in women with osteoporosis²⁶. It was also found to reduce the levels of urinary CTX-II biomarker in postmenopausal women with OA²⁷. Still, its exact role in OA is unknown and more trials are certainly needed in order to get safer and sounder results. Inhibitors of Catherpsin K are also potent DMOADs, since they could potentially affect the remodeling of both the cartilage and the subchondral bone. Nevertheless, a clinical Phase-II study performed in OA patients was prematurely stopped due to adverse effects³. Regarding estrogens, a recent 2-year clinical study examining the administration of a synthetic steroid to postmenopausal women suggested that although bone resorption can be attenuated, its positive effects on cartilage degradation could not be demonstrated²⁸.

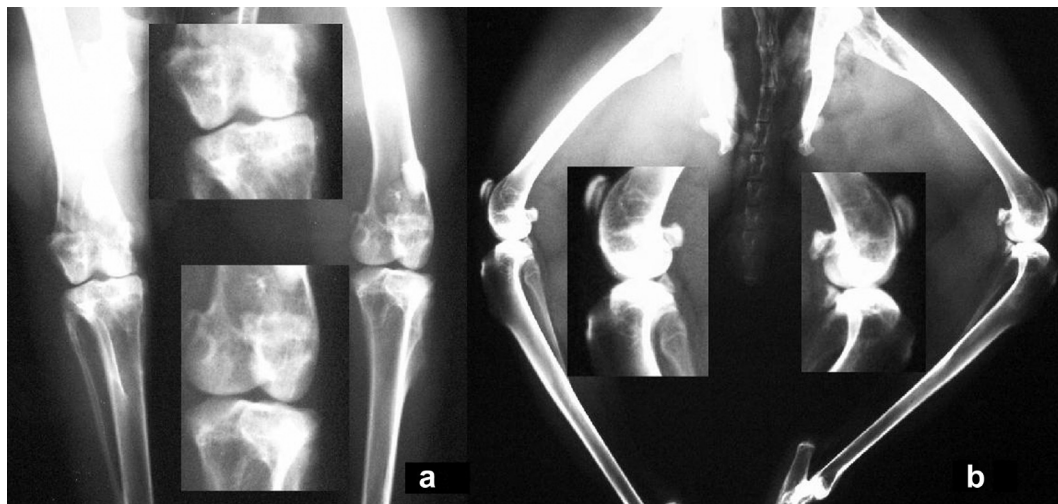


Fig. 1. a,b: Radiographs of rabbit from the placebo group that was sacrificed 1 month after the initiation of placebo administration.

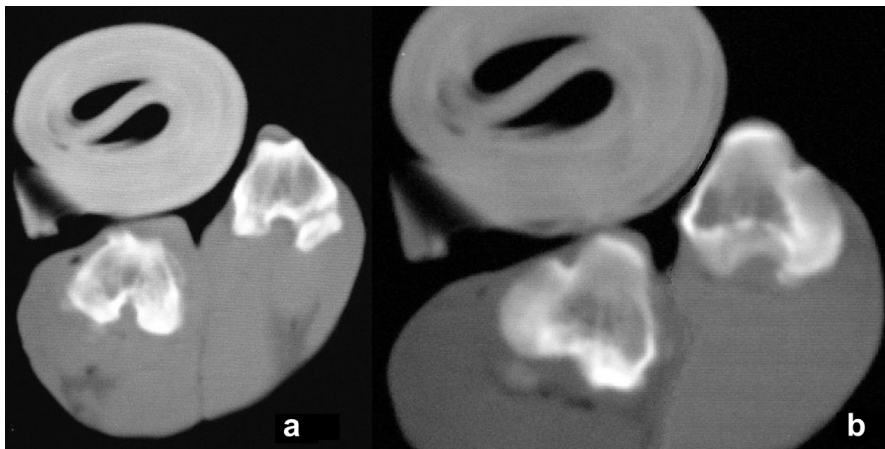


Fig. 2. a,b: CT-scan of placebo group rabbit sacrificed 1 month after initiation of administration of placebo.

Therefore, there is a constant effort to discover new pharmaceutical agents or “new potentials” for older drugs that will inhibit the progress of OA with the minimum possible side-effects. Calcitonin has been broadly used as an anti-osteoclastic agent for many years. Its safety has been widely proven, when used in the usual therapeutic doses²⁹. Its analgesic effect is also well documented^{30,31}. There seems to be evidence suggesting a direct chondroprotective effect of Calcitonin in addition to its well-established effect on bone resorption^{6,8,32,33}. This study hypothesized that articular cartilage is greatly affected by the condition of the underlying subchondral bone, therefore – and apart from its potential chondroprotective action – if Calcitonin can truly preserve the subchondral bone architecture and vitality, the result will be beneficial to the cartilage as well.

Our study implemented a unique experimental model of inducing OA which was proven to be highly successful, since all animals developed OA findings. Based on our results, Calcitonin contributed in delaying the appearance of osteoarthritic changes; therefore its action was beneficial to the articular cartilage. However, the long term beneficial effect of Calcitonin on the articular cartilage is doubted, since the results of the specimens which were

obtained from group A animals in the third month were not statistically significantly better than group B specimens.

One possible explanation for this might be the fact that the dissection of the cranial cruciate ligament combined with medial meniscectomy and a partial dissection of the medial collateral ligament, although proven to be a highly successful model, it may induce a significant destabilization of the knee. This immense instability of the joint and the resulting destruction of its cartilage may be overwhelming and subsequently may inhibit the full manifestation of the positive effect(s) of Calcitonin on the osteoarthritic cartilage. Calcitonin’s positive effect in OA is likely to be greater in OA models less severe than that used herein. Another possible explanation for the decrease of the positive effect of Calcitonin in the late stages of OA in our experimental model may be the formation of Calcitonin antibodies in rabbits after the prolonged use of Calcitonin, which may in turn inhibit its action^{34,35}. In addition to the formation of antibodies, other explanations have been also stated, such as the desensitization of Calcitonin receptors in bone and kidneys, or the formation of Calcitonin resistant bone cells as a cause of acquired resistance to Calcitonin due to large amount of Calcitonin being in the circulation³⁶.

There are many theories regarding the way Calcitonin delays the progression of OA. It may well be through the beneficial effect exerted on the subchondral bone, since it is not clear whether the

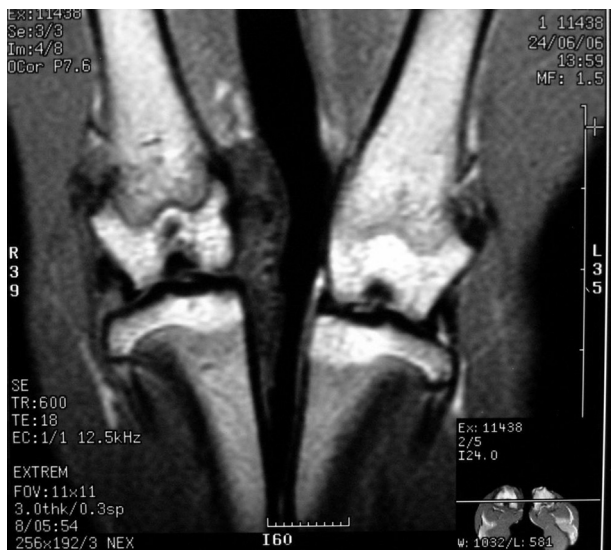

Fig. 3. MRI-scan of Calcitonin group rabbit sacrificed 1 month after initiation of administration of Calcitonin.

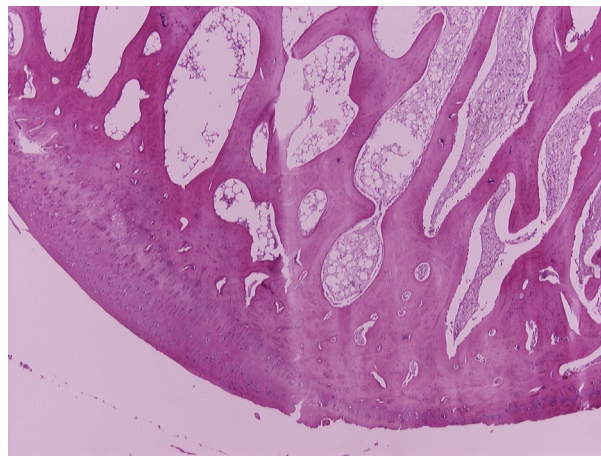


Fig. 4. Microscopic photograph (40× magnification) of articular cartilage and denuded subchondral bone in the femur of a rabbit of the placebo group.

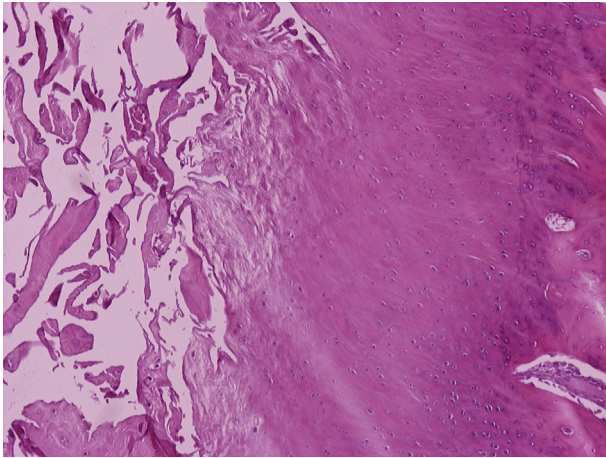


Fig. 5. Microscopic photograph (100× magnification) of fibrillation of the articular cartilage in the femur of a rabbit of the Calcitonin group.

changes of the subchondral bone precede or follow the degeneration of the articular cartilage³⁷. Pathological changes in the subchondral bone are not necessary for the initiation of OA. Nevertheless, once they appear, they negatively affect its progression³⁸, even though not all cartilage damage leads to OA³⁹.

Calcitonin is also known to stimulate glucosaminoglycan synthesis⁴⁰ and to increase the calcium uptake⁴¹, therefore it may directly affect the cartilage metabolism. The latter has been observed in several 'in vitro' studies, since Calcitonin was found to stimulate in the chondrocytes of the cartilage the production of proteoglycans and collagen type-II^{42,43}. The latter has been verified in animal studies as well, and especially in the earlier stages of OA^{5,7}. Calcitonin has also been found to increase the layer of the articular cartilage⁴⁴. This action is possibly associated with the increase of the polypeptide content of the cartilage due to activation

of ornithine decarboxylase, an enzyme that is important for the production of proteins. This assumption is further supported by the fact that Calcitonin, as Insulin and Parathyroid Hormone, increase the multiplication of rabbit cultivated chondrocytes⁴⁵.

It is not quite clear yet, whether Calcitonin exerts an anti-inflammatory action as well. It has been observed that the synovitis that co-exists in OA accelerates the degeneration of articular cartilage and the degradation of the subchondral bone and is mainly mediated by IL-1⁴⁶. Calcitonin inhibits IL-1 actions⁴⁷ and therefore it suppresses synovitis as well. IL-1 activates and promotes the degradation of calcified collagen. Calcitonin inhibits the release of Ca⁺⁺ and therefore inhibits this action of IL-1 as well⁴⁸.

Regardless of the actual mechanism of action, the beneficial effect(s) of Calcitonin have been documented in other experimental studies as well. Our findings were in accordance with similar studies regarding the effect exerted by Calcitonin on OA^{49–52}. Papaioannou *et al.*⁴⁹ in an experimental model of OA with section of the cranial cruciate ligament in thirty New Zealand white rabbits and administration of Calcitonin reported that their macroscopic and histological findings supported the therapeutic effect of Calcitonin on OA. Behets *et al.*⁵¹ in their experimental study in 12 dogs with transection of the anterior cruciate ligament of the right knee and administration of nasal spray of Calcitonin concluded that Calcitonin reduced cartilage OA lesions and thus might be useful in the treatment of OA in cruciate-deficient joints. Manicourt *et al.*⁵⁰ utilized 28 dogs in an experimental study to evaluate the effect of Calcitonin in OA. Their OA model implemented the transection of the anterior cruciate ligament (ACL). The authors stated that treatment with Calcitonin after ACL transection helped slow down the development of degenerative changes and therefore may have therapeutic benefits for humans who recently had a traumatic knee joint injury. The most recent experimental study regarding Calcitonin and its potential use in the treatment of OA was performed by Nielsen *et al.*⁵² The OA model used in this study was bilateral partial medial meniscectomy in rats and Calcitonin was orally administered. The authors' conclusion was that orally administered salmon Calcitonin significantly reduced the damage in the calcified cartilage and the subchondral bone, especially in the rabbits that had been ovariectomized as well.

It is extremely difficult to perform such a study without making several compromises. Therefore this study has certain limitations as well. The reader should be aware of the fact that the hereby presented animal osteoarthritic model seems to be a rather drastic one. As each one of the three implemented surgical procedures can by itself induce knee OA, it is worth stressing that Calcitonin slows down OA disease progression in a model induced by summing the three different surgical approaches. Summing the three procedures induces a significant destabilization of the knee and thereby, induces impressive changes in the distribution of biomechanical forces into the joint. Accordingly, the severity and speed of onset of OA following combination of destabilization procedures in rabbit knee does not parallel the OA disease in humans and may limit the relevance of the model. Furthermore, since important biomechanical stresses following the extensive destabilization procedure are expected to overcome the inherent biomechanical properties of joint components, it is unlikely any medical treatment will prevent cartilage degradation in the experimental model reported herein. Based on all the pre-mentioned, the reader should be aware of the fact that this osteoarthritic model, as well as other similar osteoarthritic models, does not necessarily replicate all facets of the OA disease process in humans.

It is well understood that OA needs a multidisciplinary therapeutic approach. Several drugs' categories have been developed aiming to treat patients suffering from OA. None of them however seems to be 100% effective, especially when other well established

Table II
Statistically significant results

Month of sacrifice	Group	Imaging score	Mean imaging score and deviations	P
<i>Femoral condyles</i>				
First	Calcitonin	4 4 7	5.0 (1,7)	0.046
	Placebo	10 11 13	11.33 (1,5)	
Second	Calcitonin	12 14	14.33 (2,5)	0.046
	Placebo	17 18 18 21	19.0 (1,7)	
<i>Tibial Condyles</i>				
Second	Calcitonin	12 14 17	14.33 (2,51)	0.046
	Placebo	18 20 20	19.33 (1,15)	
<i>Stage (area in percentage) of osteoarthritic lesion in tibial condyles</i>				
Month of sacrifice	Group	Stage (%)	Mean stage (%) and deviations	P
Second	Calcitonin	20.9 15.41 9.13	15.14 (5,88)	0.05
	Placebo	31.78 26.585 26.62	28.32 (2,98)	

contributing factors (i.e., weight, mechanical axis of the limb, joint luxation) are not taken into account as well. In this context, Calcitonin seems to fulfill many of the requested criteria for a potent anti OA drug. Given its safety record, it seems that the early administration of Calcitonin in humans may contribute in delaying the progression of OA. Nevertheless, and since the expression⁵³ or not⁵⁴ of Calcitonin receptor in the human cartilage and chondrocyte has not been clarified yet, prospective clinical studies are certainly needed in order to confirm the results of this experimental paper, especially when taking into account the fact that orally administered Calcitonin as well may have a promising role in the treatment of OA in the near future^{55–57}.

Author contributions statement

All authors have made substantial contributions to all three of sections below:

- the conception and design of the study, acquisition of data, analysis and interpretation of data.
- drafting the article or revising it critically for important intellectual content
- final approval of the version to be submitted.

Margaritis J Kyrkos (mjkyrkos@hotmail.com) is the author responsible for the integrity of the work as a whole, from inception to finished article.

Ethical board review statement

This study was approved by our institution's scientific research board and our animal utilization study committee (13/12631/2-10-2006).

Conflict of interest statement/role of the funding source

The authors certify that they have no commercial associations (e.g., consultancies, stock ownership, equity interest, patent/licensing arrangements, etc) or funding sources that might pose a conflict of interest in connection with the submitted article.

Acknowledgments

The authors would like to express their gratitude to Professor Prodromos Hytiroglou for his valuable assistance in processing and evaluating the histological specimens.

References

1. Helmick CG, Felson DT, Lawrence RC, Gabriel S, Hirsch R, Kwoh CK, *et al.* Estimates of the prevalence of arthritis and other rheumatic conditions in the United States. Part I. *Arthritis Rheum* 2008;58(1):15–25.
2. Maetzel A, Li LC, Pencharz J, Tomlinson G, Bombardier C. The economic burden associated with osteoarthritis, rheumatoid arthritis, and hypertension: a comparative study. *Ann Rheum Dis* 2004;63:395–401.
3. Martel-Pelletier J, Wildi LM, Pelletier JP. Future therapeutics for osteoarthritis. *Bone* 2012;51:297–311.
4. Hunter W. Of the structure and disease of articulating cartilages. 1743. *Clin Orthop Relat Res* 1995:3–6.
5. Sondergaard BC, Catala-Lehnen P, Huebner AK, Bay-Jensen AC, Schinke T, Henriksen K, *et al.* Mice over-expressing salmon calcitonin have strongly attenuated osteoarthritic histopathological changes after destabilization of the medial meniscus. *Osteoarthritis Cartilage* 2012;20(2):136–43.
6. Karsdal MA, Sondergaard BC, Arnold M, Christiansen C. Calcitonin affects both bone and cartilage: a dual action treatment for osteoarthritis? *Ann N Y Acad Sci* 2007;1117:181–95.
7. El Hajjaji H, Williams JM, Devogelaer JP, Lenz ME, Thonar EJ, Manicourt DH. Treatment with calcitonin prevents the net loss of collagen, hyaluronan and proteoglycan aggregates from cartilage in the early stages of canine experimental osteoarthritis. *Osteoarthritis Cartilage* 2004;12:904–11.
8. Karsdal MA, Tanko LB, Riis BJ, Sondergaard BC, Henriksen K, Altman RD, *et al.* Calcitonin is involved in cartilage homeostasis: is calcitonin a treatment for OA? *Osteoarthritis Cartilage* 2006 Jul;14(7):617–24.
9. Chesnut 3rd CH, Azria M, Silverman S, Engelhardt M, Olson M, Mindeholm L. Salmon calcitonin: a review of current and future therapeutic indications. *Osteoporos Int* 2008;19:479–91.
10. Hulth A, Lindberg L, Telhag H. Experimental osteoarthritis in rabbits. Preliminary report. *Acta Orthop Scand* 1970;41:522–30.
11. Colombo C, Butler M, O'Byrne E, Hickman L, Swartzendruber D, Selwyn M, *et al.* A new model of osteoarthritis in rabbits. I. Development of knee joint pathology following lateral meniscectomy and section of the fibular collateral and sesamoid ligaments. *Arthritis Rheum* 1983;26(7):875–86.
12. Kawano T, Miura H, Mawatari T, Moro-Oka T, Nakanishi Y, Higaki H, *et al.* Mechanical effects of the intraarticular administration of high molecular weight hyaluronic acid plus phospholipid on synovial joint lubrication and prevention of articular cartilage degeneration in experimental osteoarthritis. *Arthritis Rheum* 2003;48(7):1923–9.
13. Chan WP, Lang P, Stevens MP, Sack K, Majumdar S, Stoller DW, *et al.* Osteoarthritis of the knee: comparison of radiography, CT, and MR imaging to assess extent and severity. *AJR Am J Roentgenol* 1991;157(4):799–806.
14. Pritzker KP, Gay S, Jimenez SA, Ostergaard K, Pelletier JP, Revell PA, *et al.* Osteoarthritis cartilage histopathology: grading and staging. *Osteoarthritis Cartilage* 2006;14(1):13–29.
15. Arden N, Nevitt MC. Osteoarthritis: epidemiology. *Best Pract Res Clin Rheumatol* 2006;20:3–25.
16. Felson DT. Clinical practice. Osteoarthritis of the knee. *N Engl J Med* 2006;354:841–8.
17. Johnson AG, Nguyen TV, Day RO. Do nonsteroidal anti-inflammatory drugs affect blood pressure? A meta-analysis. *Ann Intern Med* 1994;121:289–300.
18. Warner TD, Giuliano F, Vojnovic I, Bukasa A, Mitchell JA, Vane JR. Nonsteroid drug selectivities for cyclo-oxygenase-1 rather than cyclo-oxygenase-2 are associated with human gastrointestinal toxicity: a full in vitro analysis. *Proc Natl Acad Sci U S A* 1999;96:7563–8.
19. Dougados M, Nguyen M, Berdah L, Mazieres B, Vignon E, Lequesne M. Evaluation of the structure-modifying effects of diacerein in hip osteoarthritis: ECHODIAH, a three-year, placebo-controlled trial. Evaluation of the chondromodulating effect of diacerein in OA of the hip. *Arthritis Rheum* 2001;44:2539–47.
20. Pavelka K, Gatterova J, Olejarova M, Machacek S, Giacovelli G, Rovati LC. Glucosamine sulfate use and delay of progression of knee osteoarthritis: a 3-year, randomized, placebo-controlled, double-blind study. *Arch Intern Med* 2002;162:2113–23.
21. Rintelen B, Neumann K, Leeb BF. A meta-analysis of controlled clinical studies with diacerein in the treatment of osteoarthritis. *Arch Intern Med* 2006;166:1899–906.
22. Clegg DO, Reda DJ, Harris CL, Klein MA, O'Dell JR, Hooper MM, *et al.* Glucosamine, chondroitin sulfate, and the two in combination for painful knee osteoarthritis. *N Engl J Med* 2006;354(8):795–808.

23. Wang CT, Lin J, Chang CJ, Lin YT, Hou SM. Therapeutic effects of hyaluronic acid on osteoarthritis of the knee. A meta-analysis of randomized controlled trials. *J Bone Joint Surg Am* 2004;86-A:538–45.
24. Spector TD, Conaghan PG, Buckland-Wright JC, Garnero P, Cline GA, Beary JF, et al. Effect of risedronate on joint structure and symptoms of knee osteoarthritis: results of the BRISK randomized, controlled trial [ISRCTN01928173]. *Arthritis Res Ther* 2005;7(3):R625–33.
25. Bingham 3rd CO, Buckland-Wright JC, Garnero P, Cohen SB, Dougados M, Adami S, et al. Risedronate decreases biochemical markers of cartilage degradation but does not decrease symptoms or slow radiographic progression in patients with medial compartment osteoarthritis of the knee: results of the two-year multinational knee osteoarthritis structural arthritis study. *Arthritis Rheum* 2006;54(11):3494–507.
26. Bruyere O, Delferriere D, Roux C, Wark JD, Spector T, Devogelaer JP, et al. Effects of strontium ranelate on spinal osteoarthritis progression. *Ann Rheum Dis* 2008;67(3):335–9.
27. Alexandersen P, Karsdal MA, Byrjalsen I, Christiansen C. Strontium ranelate effect in postmenopausal women with different clinical levels of osteoarthritis. *Climacteric* 2011;14:236–43.
28. Karsdal MA, Byrjalsen I, Leeming DJ, Christiansen C. Tibolone inhibits bone resorption without secondary positive effects on cartilage degradation. *BMC Musculoskelet Disord* 2008;9:153.
29. Tanko LB, Bagger YZ, Alexandersen P, Devogelaer JP, Reginster JY, Chick R, et al. Safety and efficacy of a novel salmon calcitonin (sCT) technology-based oral formulation in healthy postmenopausal women: acute and 3-month effects on biomarkers of bone turnover. *J Bone Miner Res* 2004;19(9):1531–8.
30. Pun KK, Chan LW. Analgesic effect of intranasal salmon calcitonin in the treatment of osteoporotic vertebral fractures. *Clin Ther* 1989;11:205–9.
31. Badurski J, Jeziernicka E, Naruszewicz K, Racewicz A. Comparative analysis of three treatment regimens for treating gonarthrosis with calcitonin, naproxen and flavonoids based on EULAR criteria and visual analogue scale (VAS). *Pol Tyg Lek* 1995;50:37–40.
32. Sondergaard BC, Wulf H, Henriksen K, Schaller S, Oestergaard S, Qvist P, et al. Calcitonin directly attenuates collagen type II degradation by inhibition of matrix metalloproteinase expression and activity in articular chondrocytes. *Osteoarthritis Cartilage* 2006 Aug;14(8):759–68.
33. Sondergaard BC, Catala-Lehnen P, Huebner AK, Bay-Jensen AC, Schinck T, Henriksen K, et al. Mice over-expressing salmon calcitonin have strongly attenuated osteoarthritic histopathological changes after destabilization of the medial meniscus. *Osteoarthritis Cartilage* 2012 Feb;20(2):136–43.
34. Grauer A, Ziegler R, Raue F. Clinical significance of antibodies against calcitonin. *Exp Clin Endocrinol Diabetes* 1995;103:345–51.
35. Muff R, Dambacher MA, Fischer JA. Formation of neutralizing antibodies during intranasal synthetic salmon calcitonin treatment of postmenopausal osteoporosis. *Osteoporos Int* 1991;1:72–5.
36. Schipper NG, Romeijn SG, Verhoef J, Merkus FW. Hypocalcemic effect of salmon calcitonin following single and repeated nasal and intravenous administration in young rabbits. *Calcif Tissue Int* 1994;54:50–5.
37. Manicourt DH, Devogelaer JP, Azria M, Silverman S. Rationale for the potential use of calcitonin in osteoarthritis. *J Musculoskelet Neuronal Interact* 2005;5:285–93.
38. Burr DB, Schaffler MB. The involvement of subchondral mineralized tissues in osteoarthrosis: quantitative microscopic evidence. *Microsc Res Tech* 1997;37:343–57.
39. Peyron JG. Osteoarthritis. The epidemiologic viewpoint. *Clin Orthop Relat Res* 1986:13–9.
40. Baxter E, Fraser JR, Harris GS, Martin TJ, Melick RA. Stimulation of glycosaminoglycan synthesis by thyrocalcitonin preparations. *Med J Aust* 1968;1:216–7.
41. Suzuki F, Yoneda T, Shimomura Y. Calcitonin and parathyroid-hormone stimulation of acid mucopolysaccharide synthesis in cultured chondrocytes isolated from growth cartilage. *FEBS Lett* 1976;70:155–8.
42. Franchimont P, Bassleer C, Henrotin Y, Gysen P, Bassleer R. Effects of human and salmon calcitonin on human articular chondrocytes cultivated in clusters. *J Clin Endocrinol Metab* 1989;69:259–66.
43. Badurski JE, Schwamm W, Popko J, Zimnoch L, Rogowski F, Pawlica J. Chondroprotective action of salmon calcitonin in experimental arthropathies. *Calcif Tissue Int* 1991;49:27–34.
44. Kawashima K, Iwata S, Endo H. Selective activation of diaphyseal chondrocytes by parathyroid hormone, calcitonin and N₆, O₂-dibutyryl adenosine 3',5'-cyclic monophosphoric acid in proteoglycan synthesis of chick embryonic femur cultivated in vitro. *Endocrinol Jpn* 1980;27:357–61.
45. Kato Y, Nasu N, Takase T, Daikuhara Y, Suzuki F. A serum-free medium supplemented with multiplication-stimulating activity (MSA) supports both proliferation and differentiation of chondrocytes in primary culture. *Exp Cell Res* 1980;125:167–74.
46. Dieppe P, Watt I. Crystal deposition in osteoarthritis: an opportunistic event? *Clin Rheum Dis* 1985;11:367–92.
47. Gowen M, Mundy GR. Actions of recombinant interleukin 1, interleukin 2, and interferon-gamma on bone resorption in vitro. *J Immunol* 1986;136:2478–82.
48. Jilka RL, Hamilton JW. Evidence for two pathways for stimulation of collagenolysis in bone. *Calcif Tissue Int* 1985;37:300–6.
49. Papaioannou NA, Triantafillopoulos IK, Khaldi L, Krallis N, Galanos A, Lyritis GP. Effect of calcitonin in early and late stages of experimentally induced osteoarthritis. A histomorphometric study. *Osteoarthritis Cartilage* 2007;15:386–95.
50. Manicourt DH, Altman RD, Williams JM, Devogelaer JP, Druetz-Van Egeren A, Lenz ME, et al. Treatment with calcitonin suppresses the responses of bone, cartilage, and synovium in the early stages of canine experimental osteoarthritis and significantly reduces the severity of the cartilage lesions. *Arthritis Rheum* 1999;42(6):1159–67.
51. Behets C, Williams JM, Chappard D, Devogelaer JP, Manicourt DH. Effects of calcitonin on subchondral trabecular bone changes and on osteoarthritic cartilage lesions after acute anterior cruciate ligament deficiency. *J Bone Miner Res* 2004;19:1821–6.
52. Nielsen RH, Bay-Jensen AC, Byrjalsen I, Karsdal MA. Oral salmon calcitonin reduces cartilage and bone pathology in an osteoarthritis rat model with increased subchondral bone turnover. *Osteoarthritis Cartilage* 2011;19:466–73.
53. Segovia-Silvestre T, Bonnefond C, Sondergaard BC, Christensen T, Karsdal MA, Bay-Jensen AC. Identification of the calcitonin receptor in osteoarthritic chondrocytes. *BMC Res Notes* 2011;4:407.
54. Lin Z, Pavlos NJ, Cake MA, Wood DJ, Xu J, Zheng MH. Evidence that human cartilage and chondrocytes do not express calcitonin receptor. *Osteoarthritis Cartilage* 2008;16:450–7.

55. Karsdal MA, Byrjalsen I, Henriksen K, Riis BJ, Lau EM, Arnold M, *et al.* The effect of oral salmon calcitonin delivered with 5-CNAC on bone and cartilage degradation in osteoarthritic patients: a 14-day randomized study. *Osteoarthritis Cartilage* 2010 Feb;18(2):150–9.
56. Bagger YZ, Tankó LB, Alexandersen P, Karsdal MA, Olson M, Mindeholm L, *et al.* Oral salmon calcitonin induced suppression of urinary collagen type II degradation in postmenopausal women: a new potential treatment of osteoarthritis. *Bone* 2005 Sep;37(3):425–30.
57. Karsdal MA, Henriksen K, Bay-Jensen AC, Molloy B, Arnold M, John MR, *et al.* Lessons learned from the development of oral calcitonin: the first tablet formulation of a protein in phase III clinical trials. *J Clin Pharmacol* 2011 Apr;51(4):460–71.